HYBRID IMAGING

ASSOC. PROF. DR FATHINUL FIKRI AS

PUSAT PENGIMEJAN DIAGNOSTIK NUKLEAR

Hybrid Imaging

Structure imaging	Functional imaging
Computed Tomography	Positron Emission Tomography (PET)
Magnetic Resonance Img	Single Proton Emission Tomography (SPECT)
Ultrasound	MRI-DWI
X-ray	Ultrasound

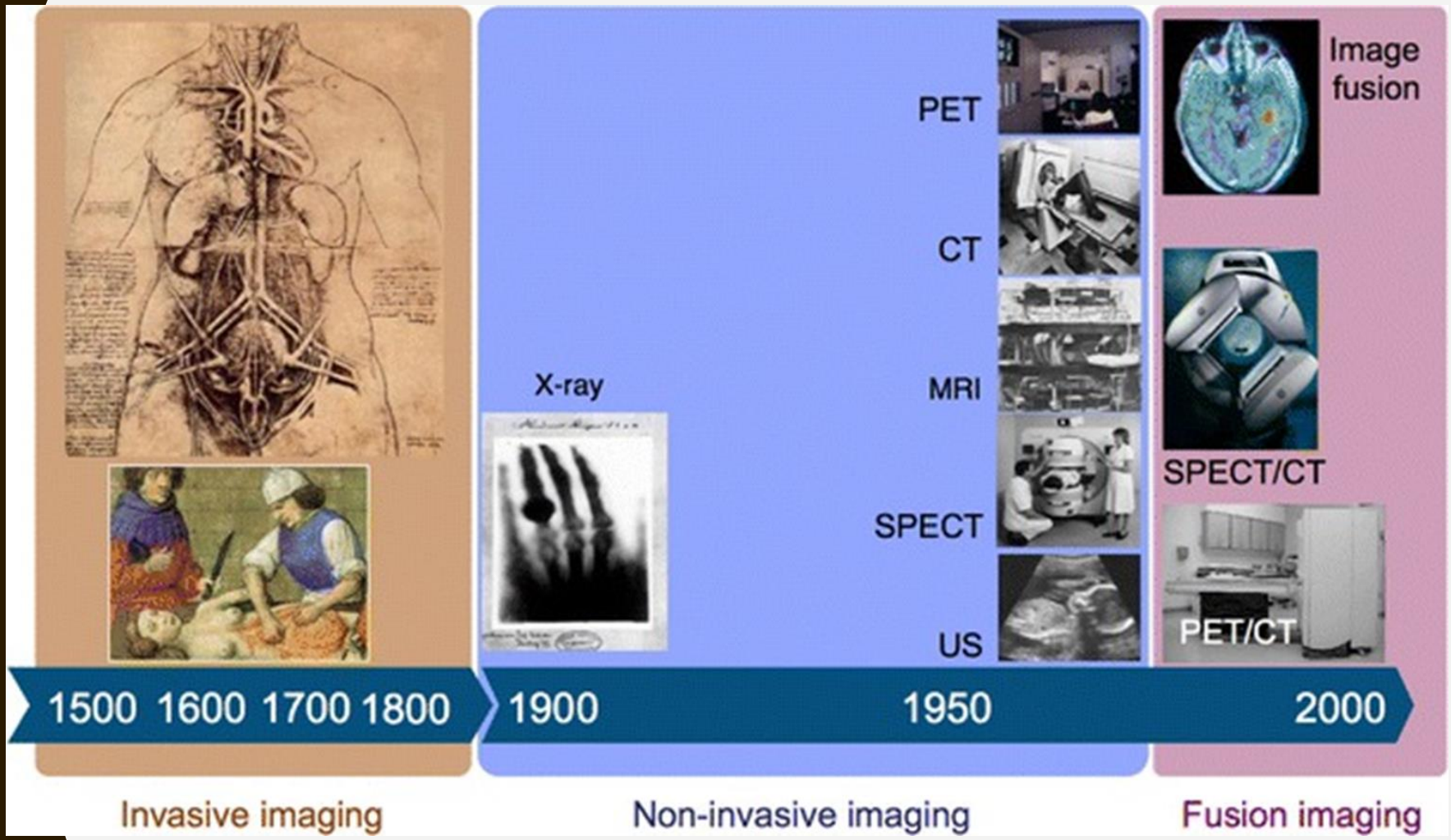
X-ray
PET
CT
MRI
SPECT
US
Image fusion
SPECT/CT
PET/CT
1500 1600 1700 1800
1900
1950
2000
Invasive imaging
Non-invasive imaging
Fusion imaging

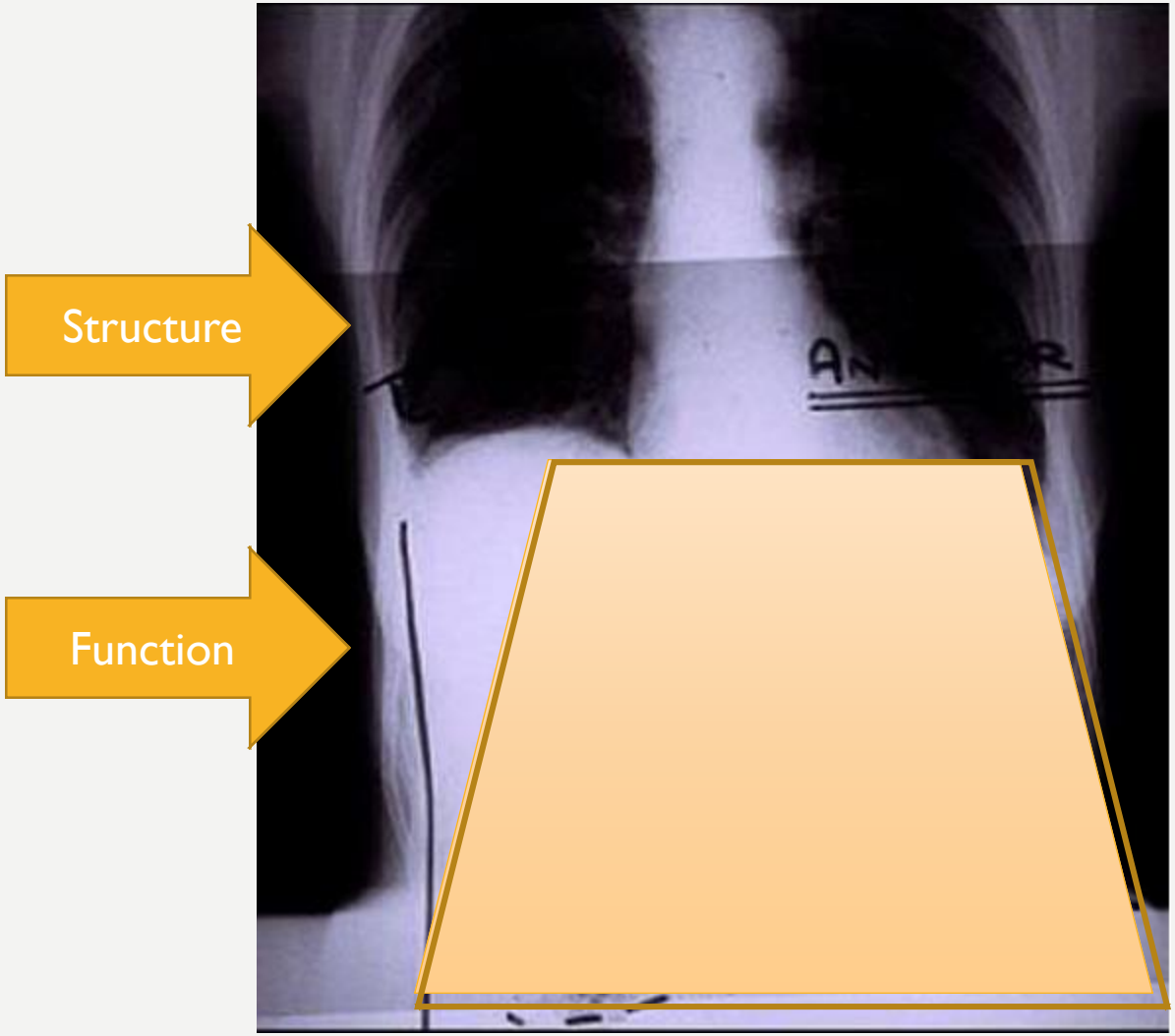

Blahd WH. Ben Cassen and the development of the rectilinear scanner. Semin Nucl Med 1996; 26(3):165-70.

1960

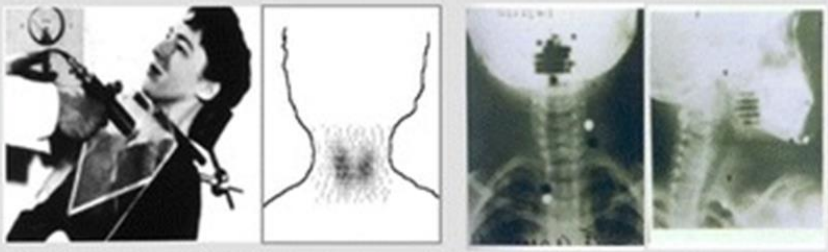

Manual contouring and image overlay

1980

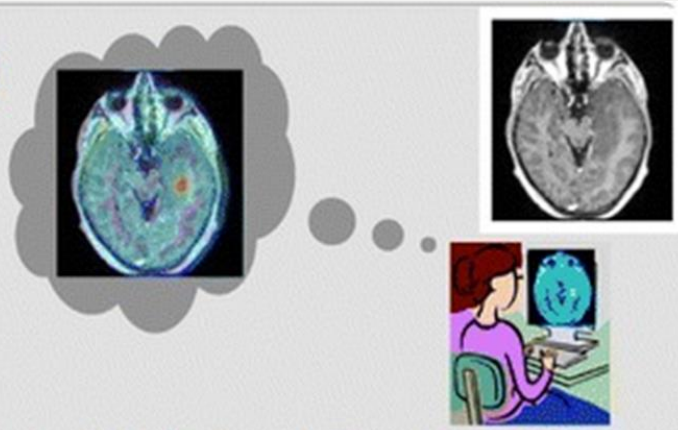

Lightbox viewing and film handling

1990

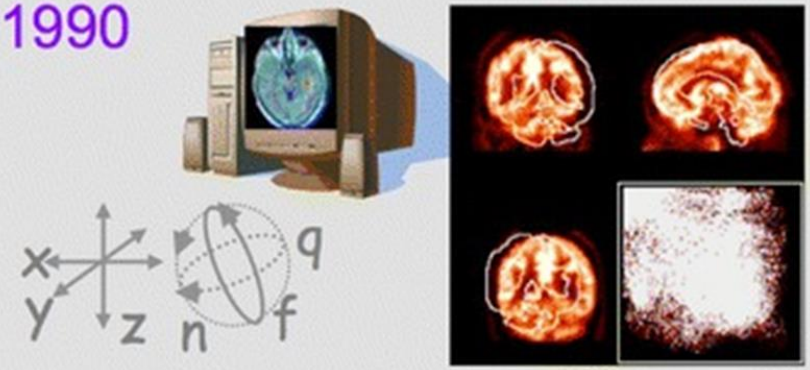

Semi-automated SW co-registration

2000

Hardware-based image fusion

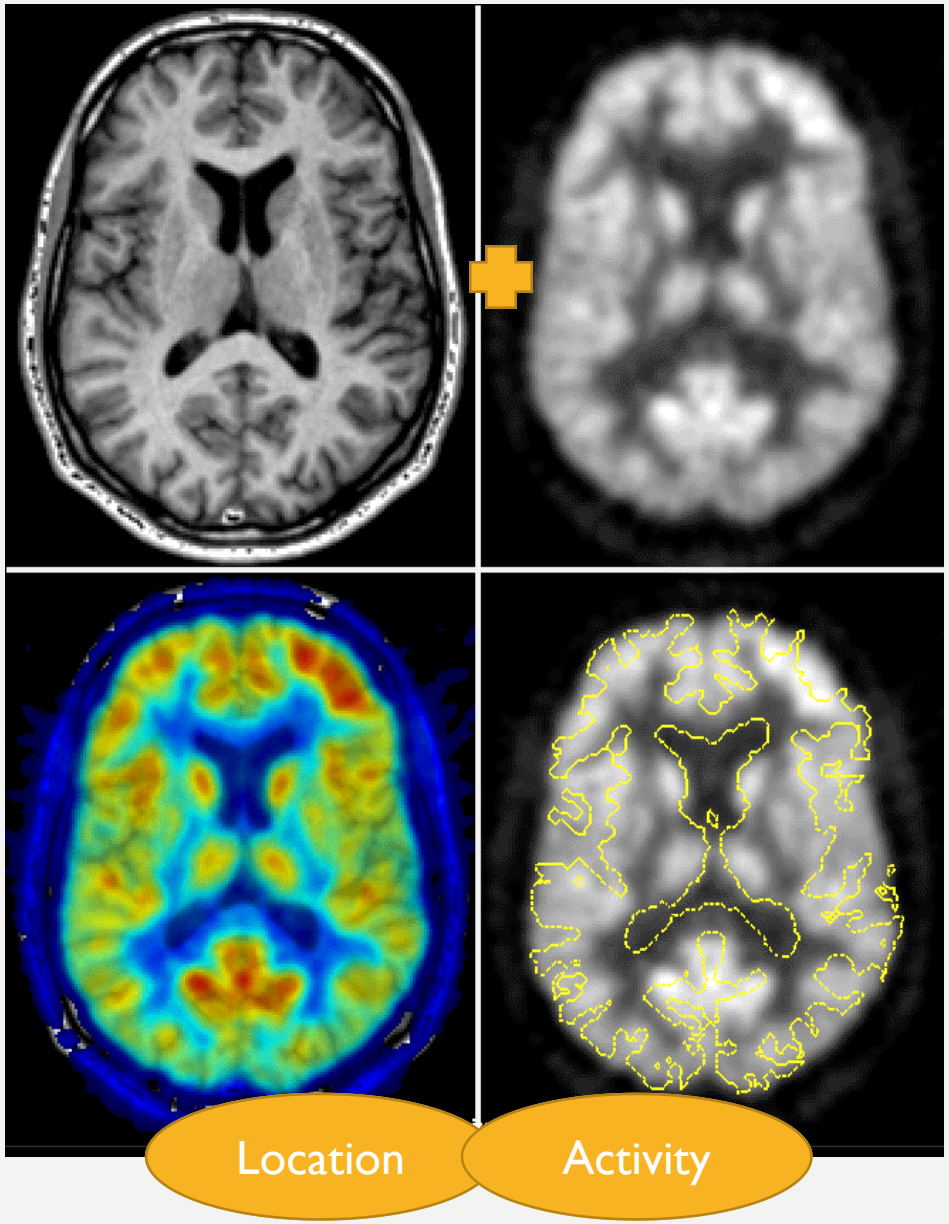
Location
Activity

WHY DO WE NEED HYBRID IMAGING ?

Standalone modality: : ONLY structure or anatomy & location

Functional information is crucial
Both structure and function:

- determines the drug efficacy
- determine prognosis
- accuracy in disease staging
- accuracy in localizing abnormal lesions
- avert complication
- save costs
- reduce hospital stay

Diagnostic Performance of Combined Noninvasive Coronary Angiography and Myocardial Perfusion Imaging Using 320-row Detector Computed Tomography:

The CORE320 Multicenter International Study

João A.C. Lima, M.D., Johns Hopkins Hospital

Incremental Value of CTA-CTP over CTA
(Reference Standard: *50% by ICA with SPECT-MPI defect)*

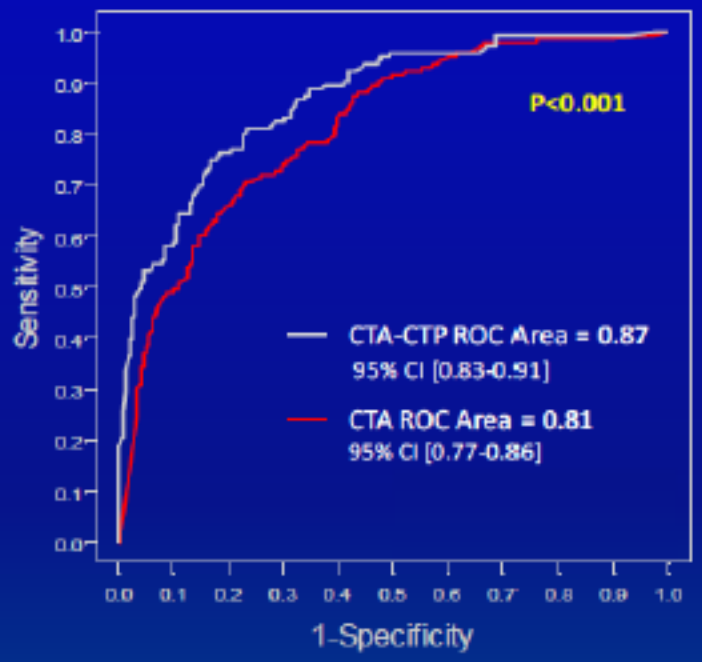

CTA-CTP vs. ICA/SPECT to predict Vessel Level Revascularization
(Reference Standard: *Revascularization at 30 days)*

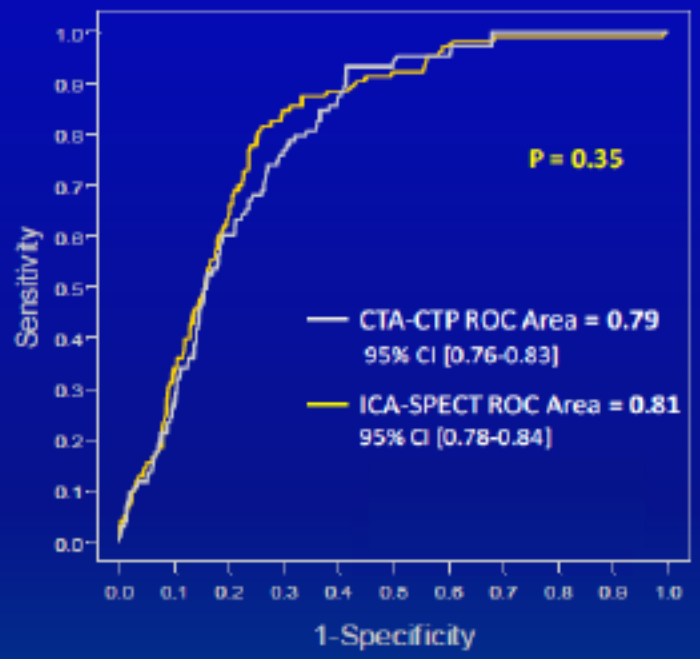

HYBRID IMAGING SYSTEMS

PET/CT
PET-MRI
FMRI(DWI)+PET
MRI-USG

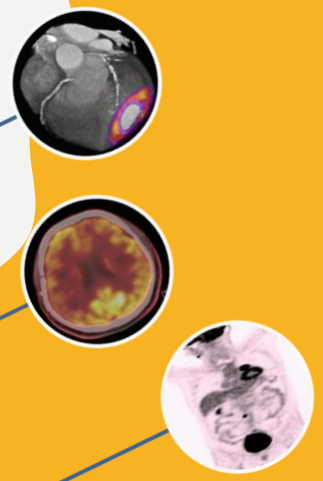

18 F- FDG PET-CT

PET -FUNCTIONAL

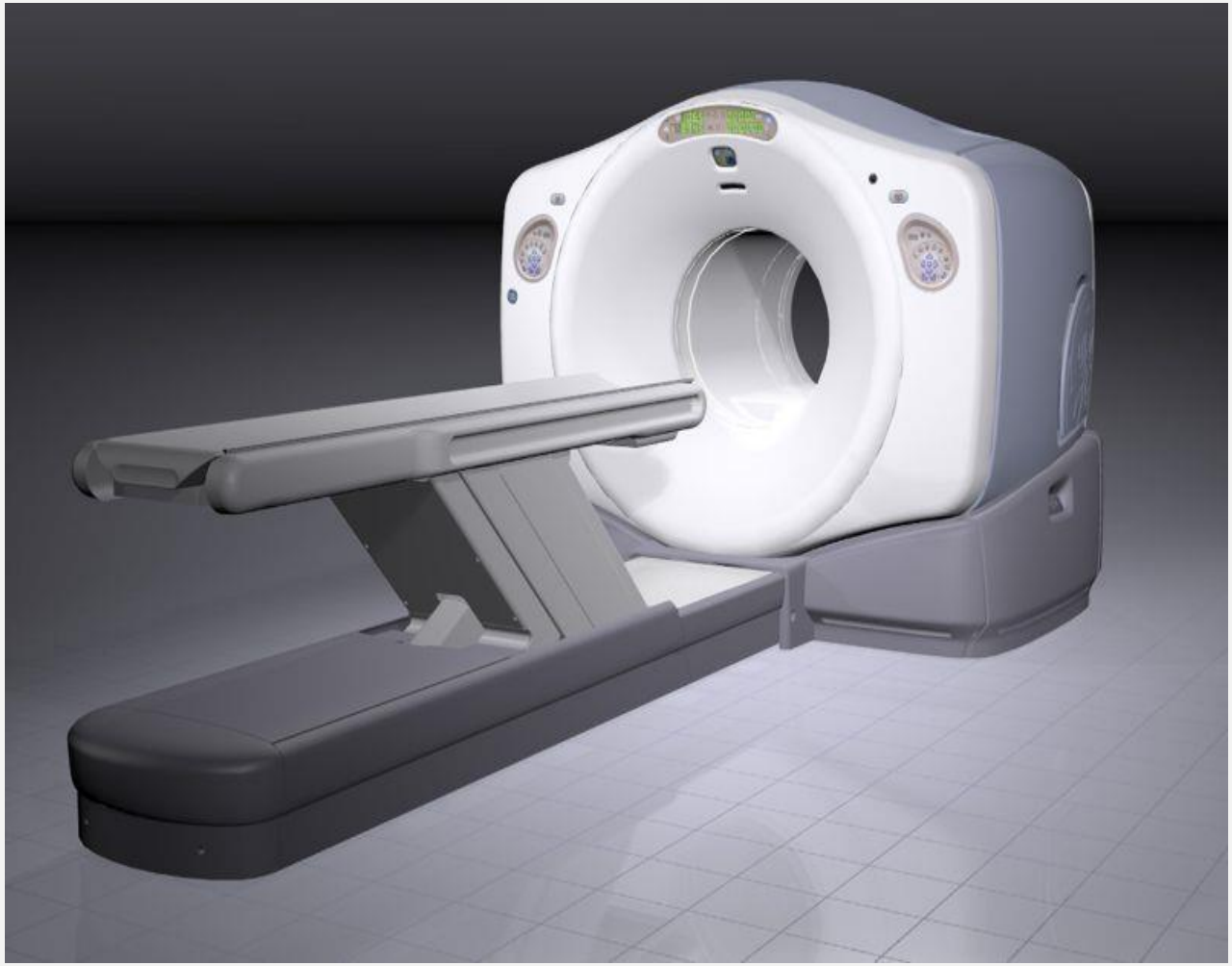

POSITRON EMISSION

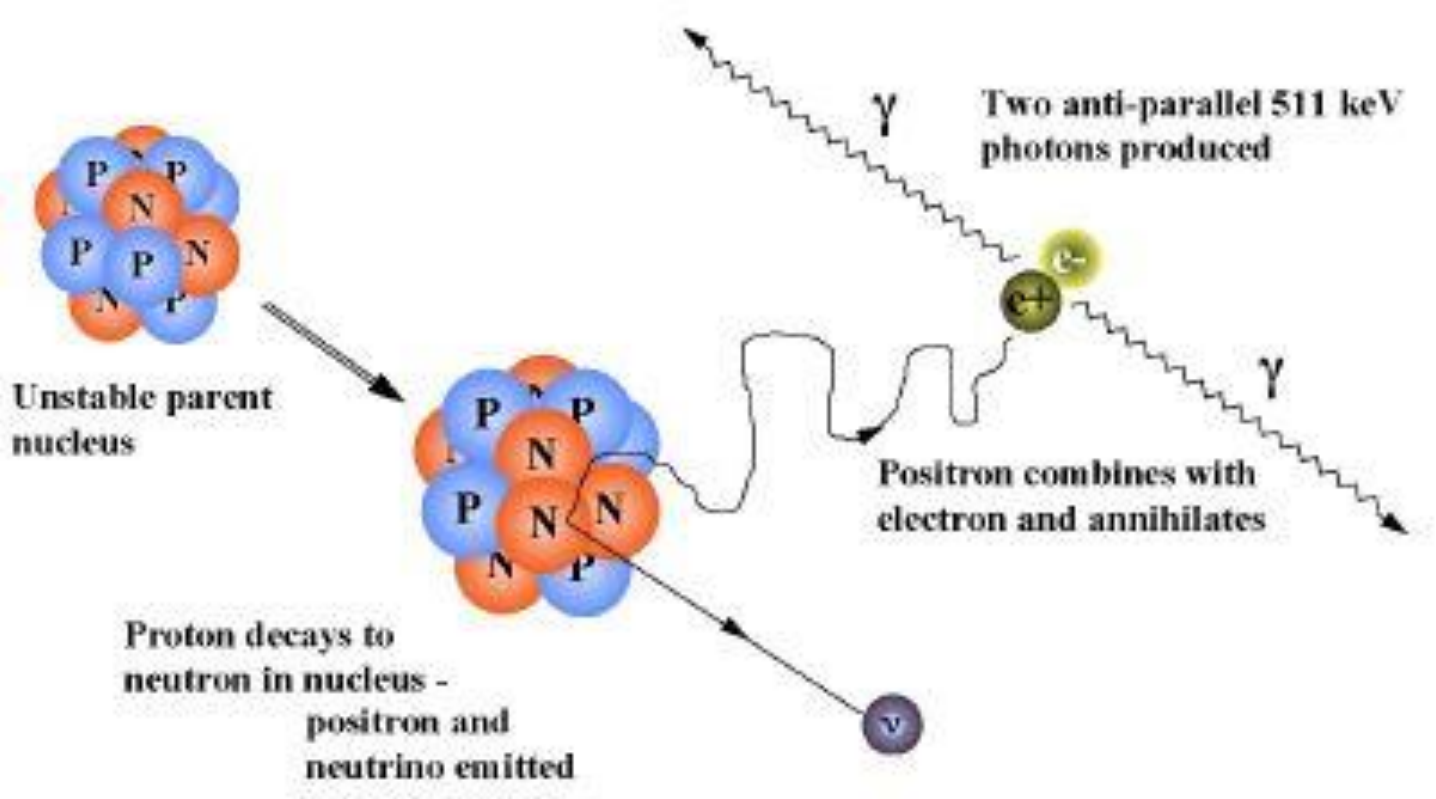

PET TECHNOLOGY

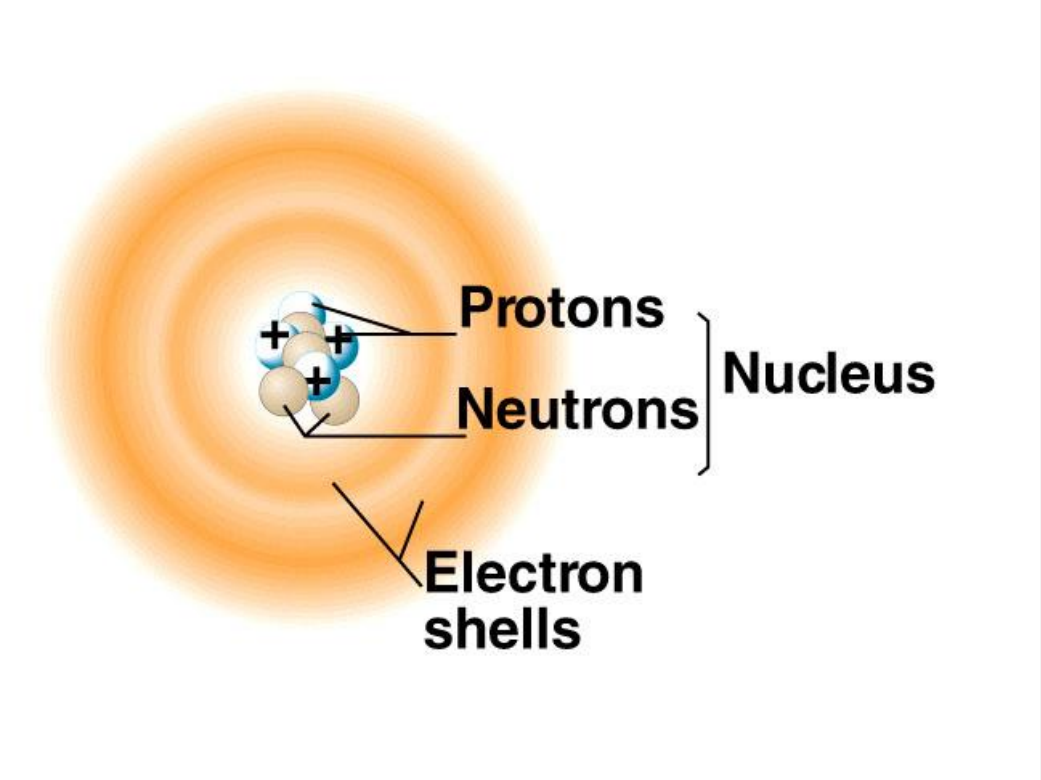

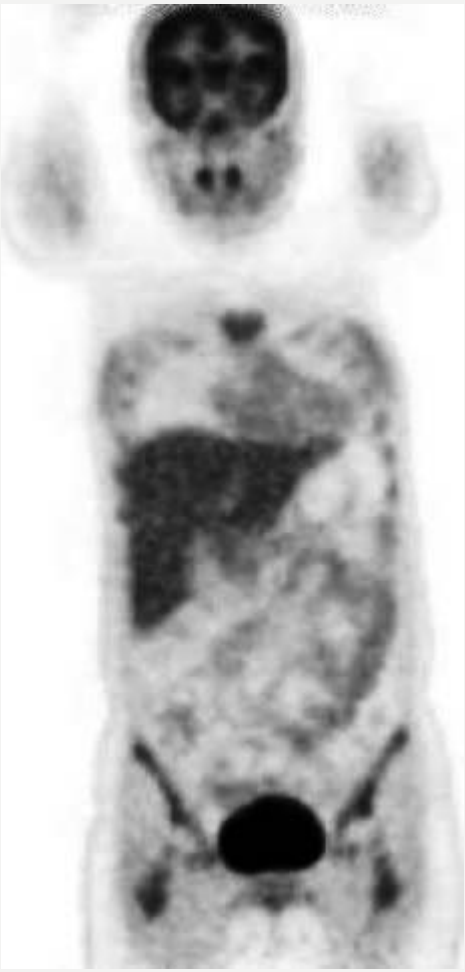

PET RADIONUCLIDES (FUNCTIONAL)

Isotope	half-life (min)	Maximum positron energy (MeV)	Positron range in water (FWHM in mm)	Production method
^{11}C	20.3	0.96	1.1	cyclotron
^{13}N	9.97	1.19	1.4	cyclotron
^{15}O	2.03	1.70	1.5	cyclotron
^{18}F	109.8	0.64	1.0	cyclotron
^{68}Ga	67.8	1.89	1.7	generator
^{82}Rb	1.26	3.15	1.7	generator

PET IMAGE ACQUISITION

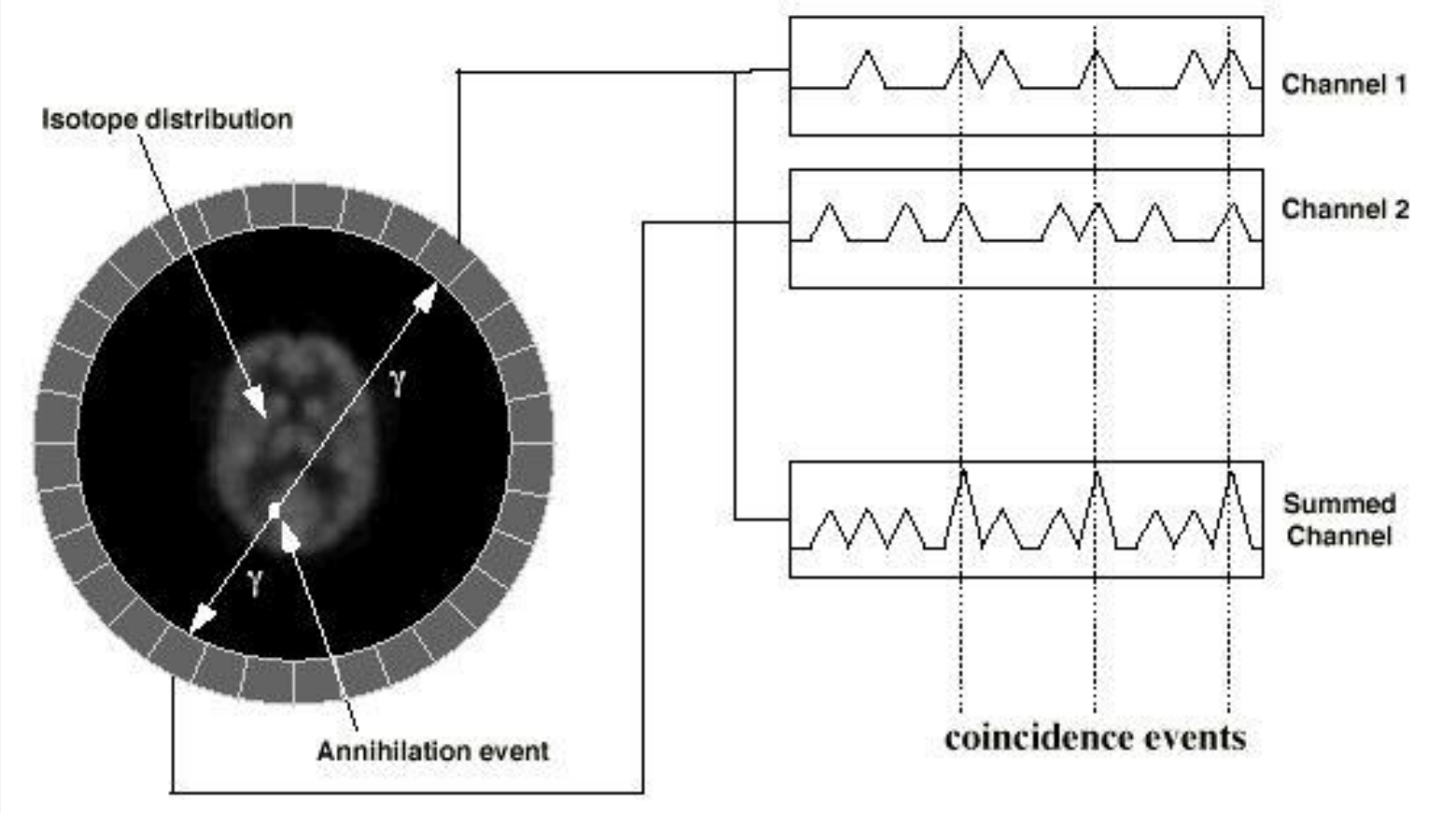

RADIOLABELLING (FUNCTIONAL)

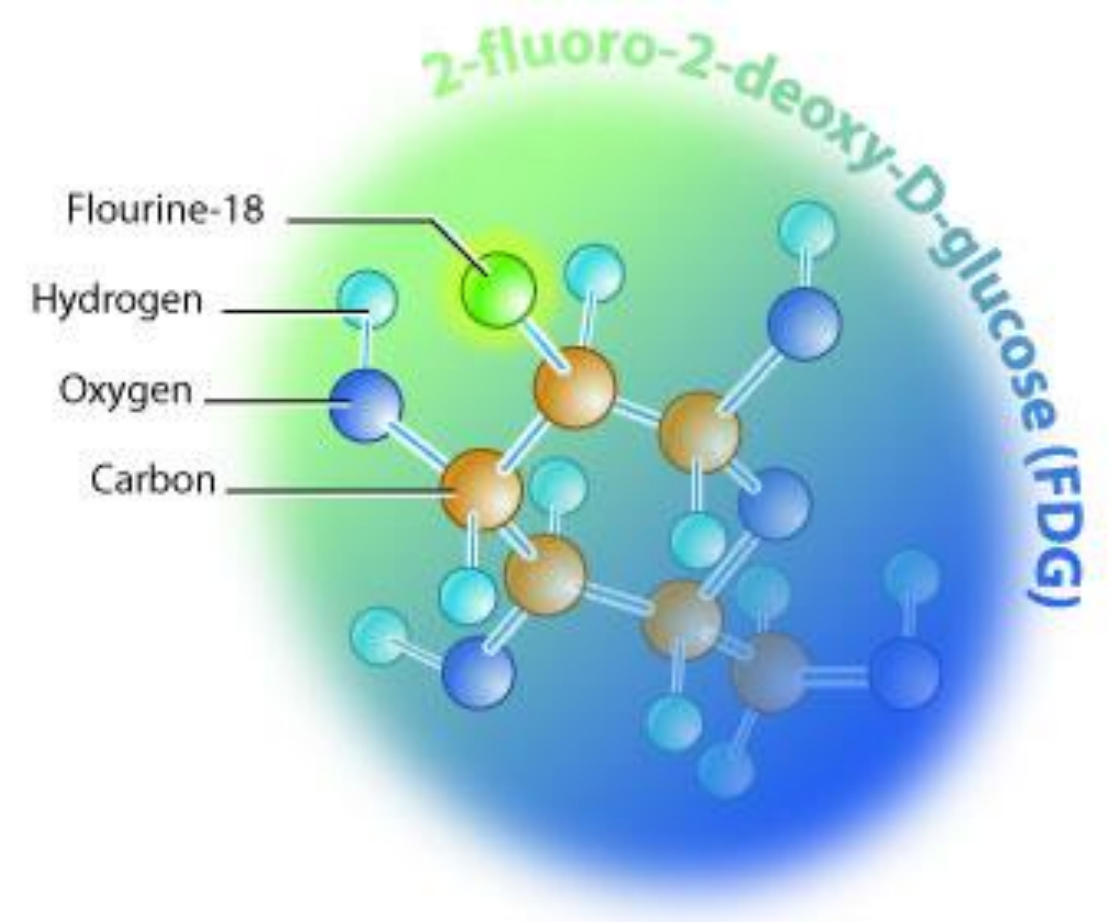

FDG AS A LIGAND

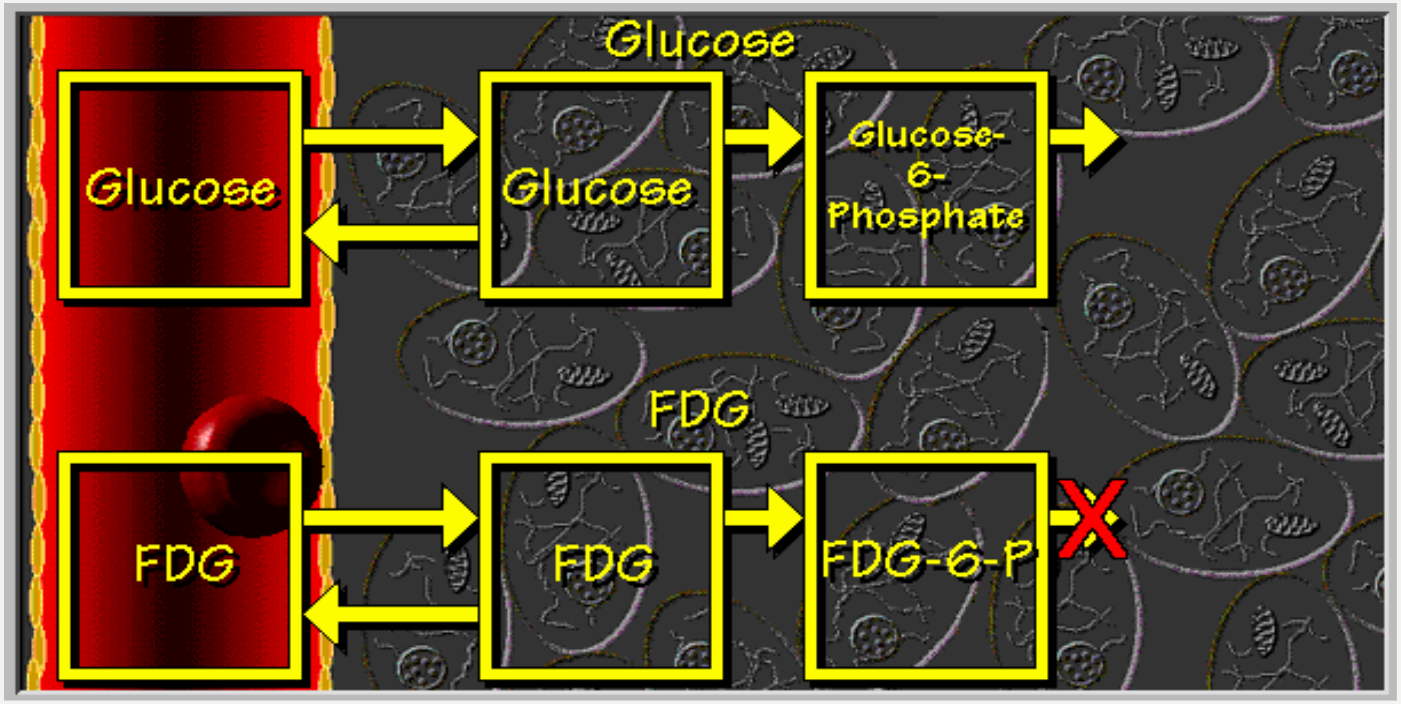

TUMOUR METABOLISM (FUNCTIONAL)

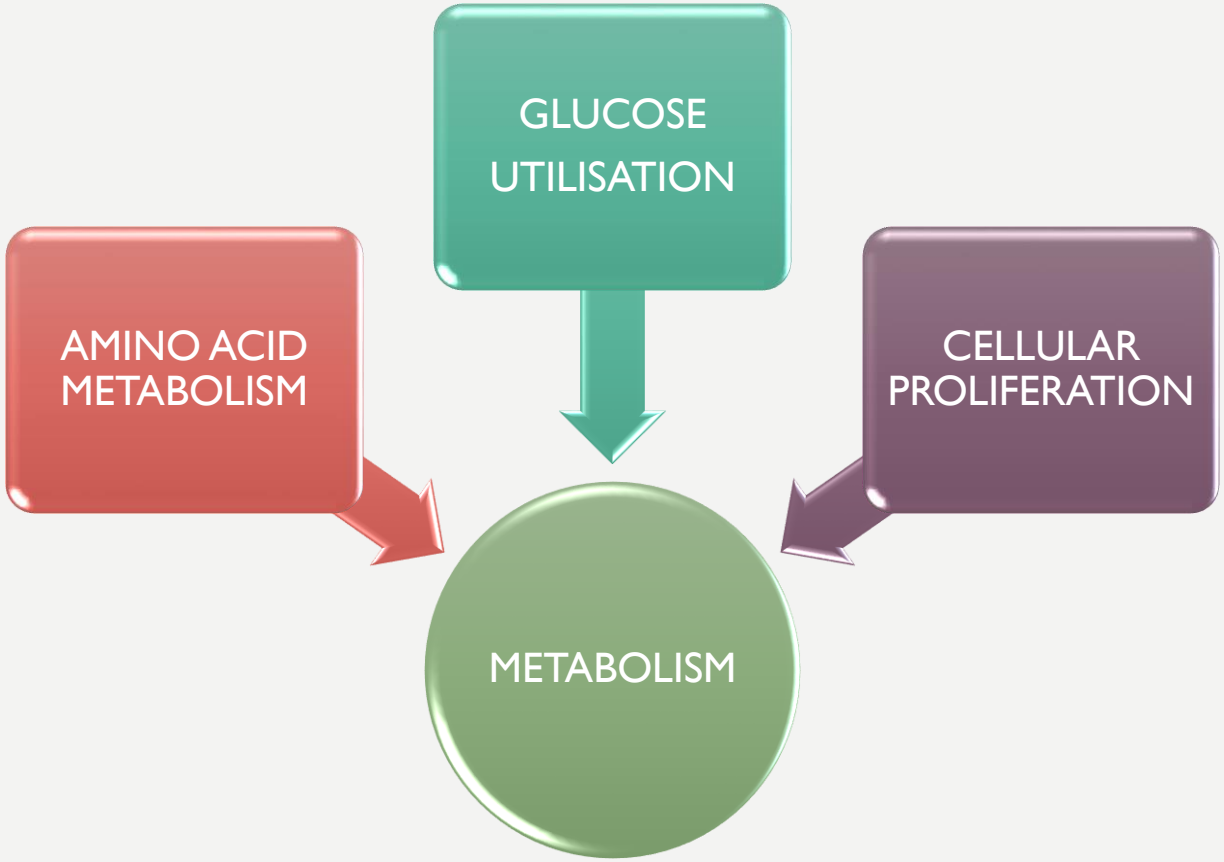

Rodney J Hicks. Beyond FDG: novel PET tracers for cancer imaging.
Cancer Imaging (2003) ***4,*** *22–24*

PET-CT ; RADIONUCLIDE COMPOUNDS

PET Radio-N	PET RN-Cmp	Signalling	Indication
18 F	18 F- FDG	glucose metabolism	lymphoma head & neck ca nsclc, melanoma, colon ca
	18-F-FET	amino acid metabolism	cancer (brain- glioma)
	18 F- FLT	tissue proliferation	cancer (brain)
	18-F-FMISO/FAZA	tissue hypoxia	cancer (gist/sarcoma)
	18-F- FCL	sterol proliferation	cancer (prostate)
68 Ga	68-Ga- Octreotate	tumour receptor overexpression	cancer (net)

A commercial PET/CT scanner design

Gantry dimensions:
228 cm x 200 cm x 168 cm

CT rotation: 0.4 s; 16 slice

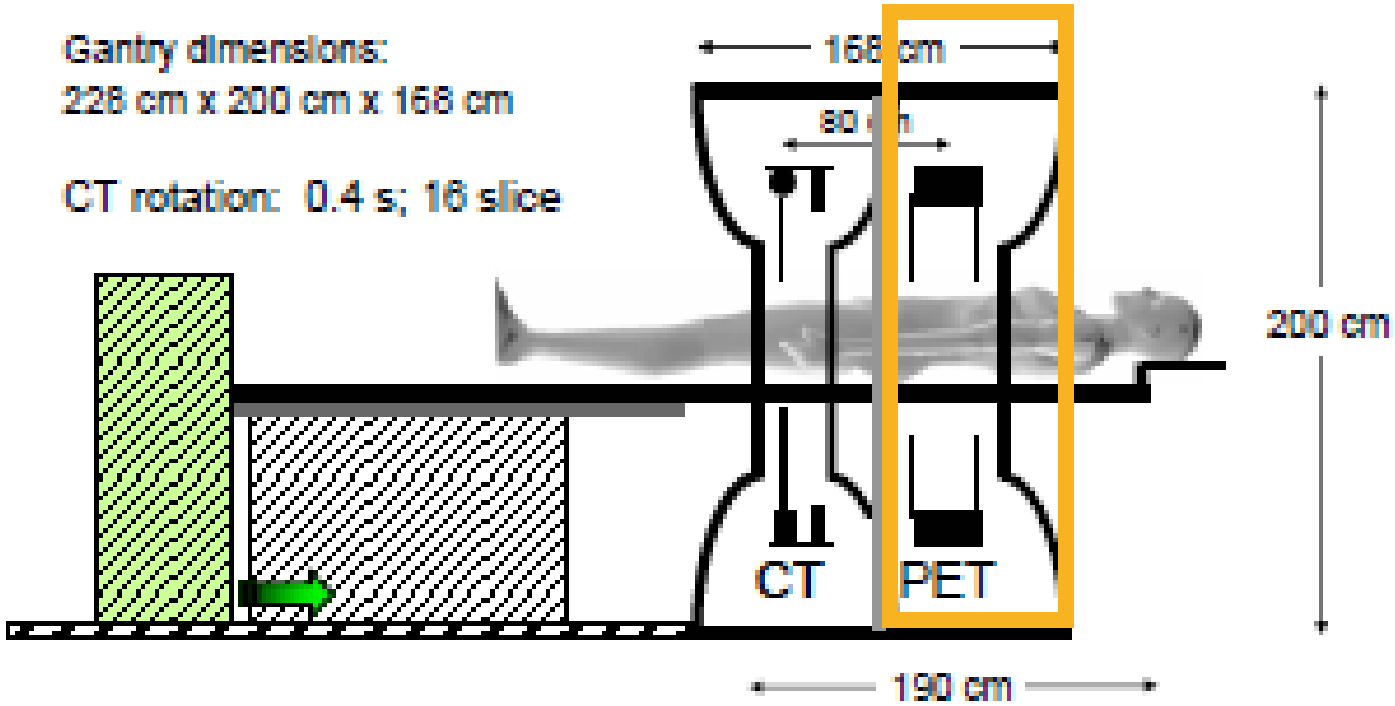

Dual-modality imaging range

HARDWARE FUSION HYBRIDIDSATION

- to image different aspects of disease
- to identify non-specific tracer uptake
- to facilitate image interpretation
- to provide unique added value to both

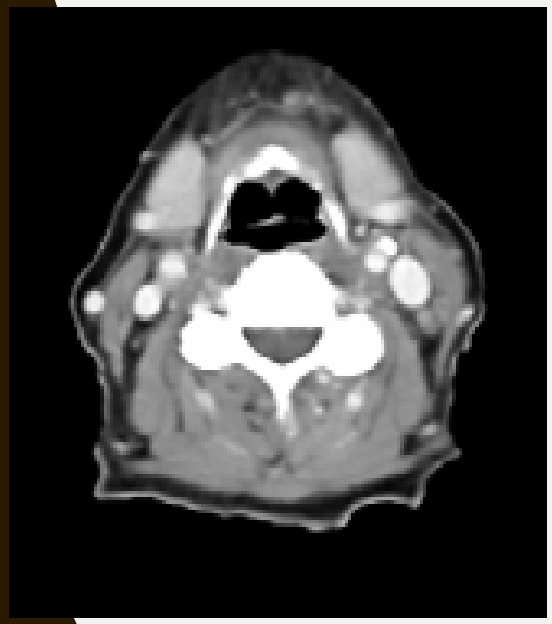



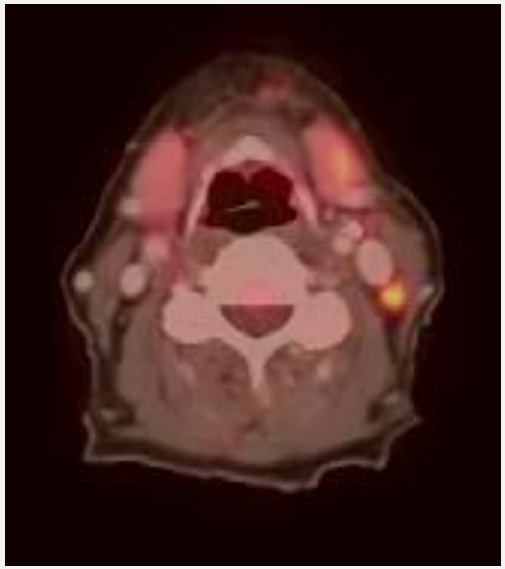

MIP IMAGE

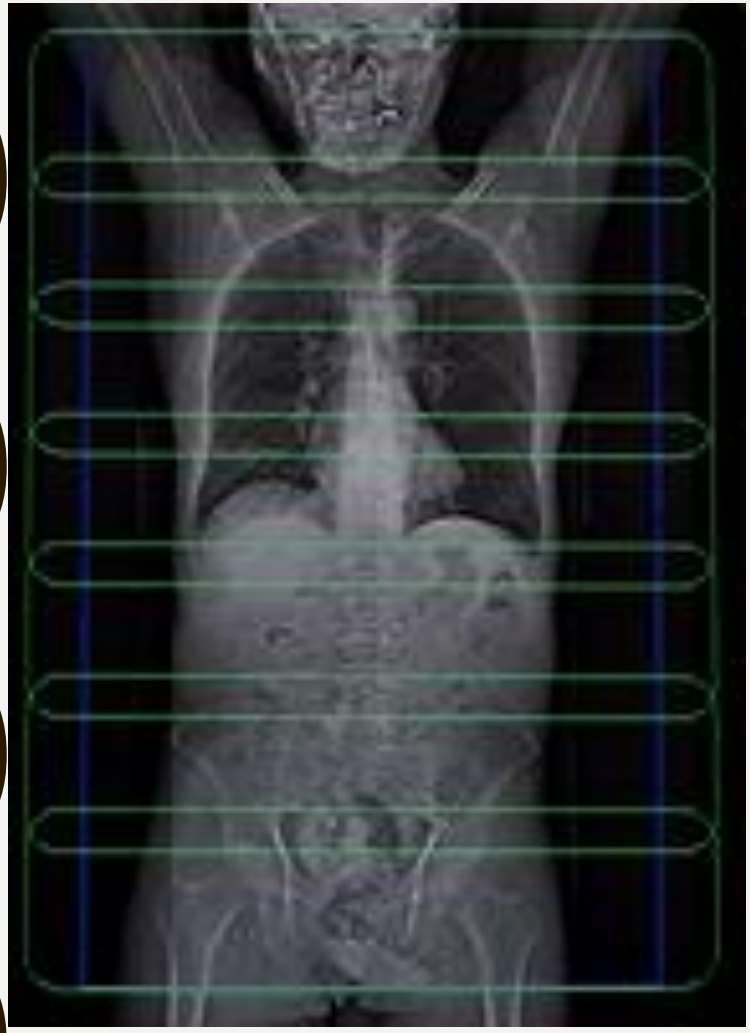

Structure

Function

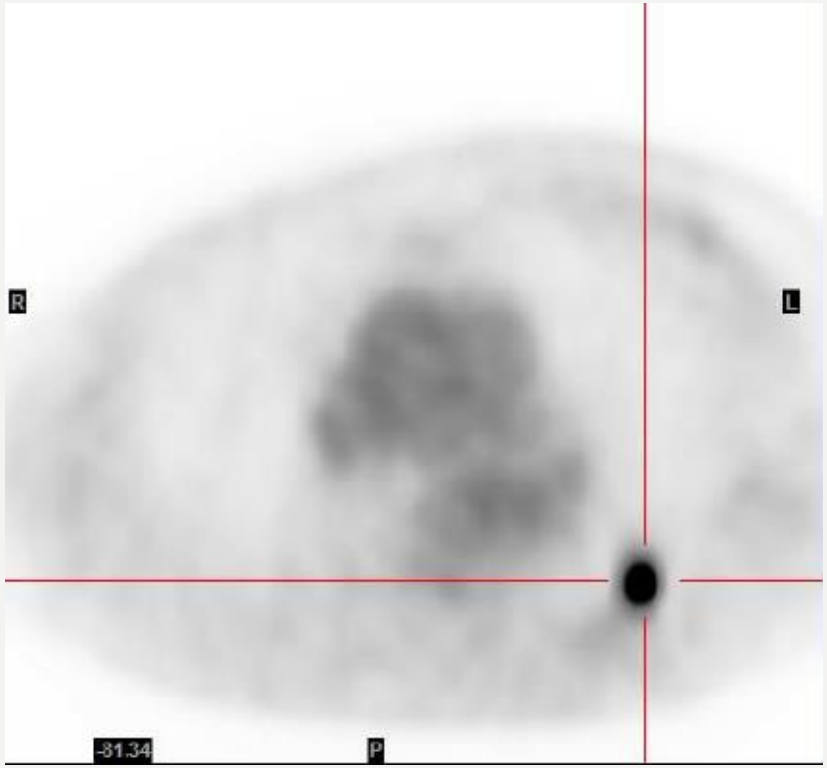

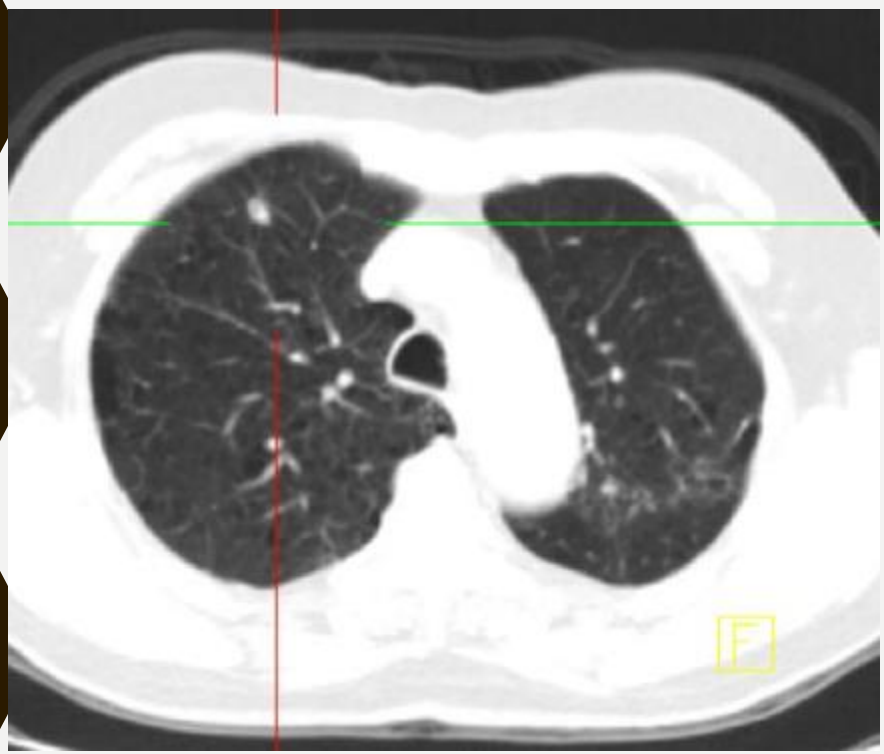

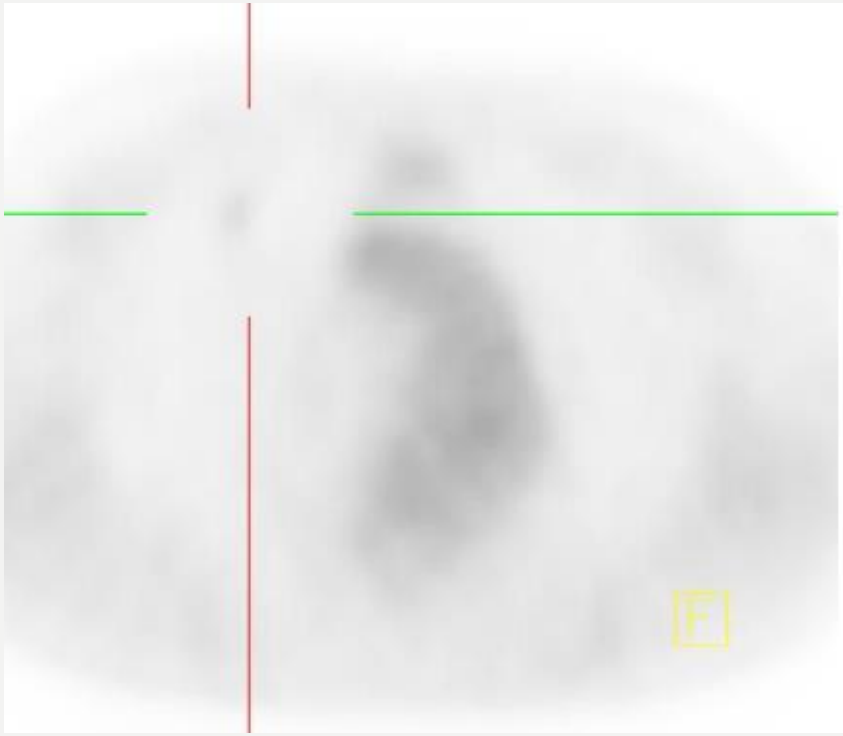

GIT TUMOUR (T2N1M0)

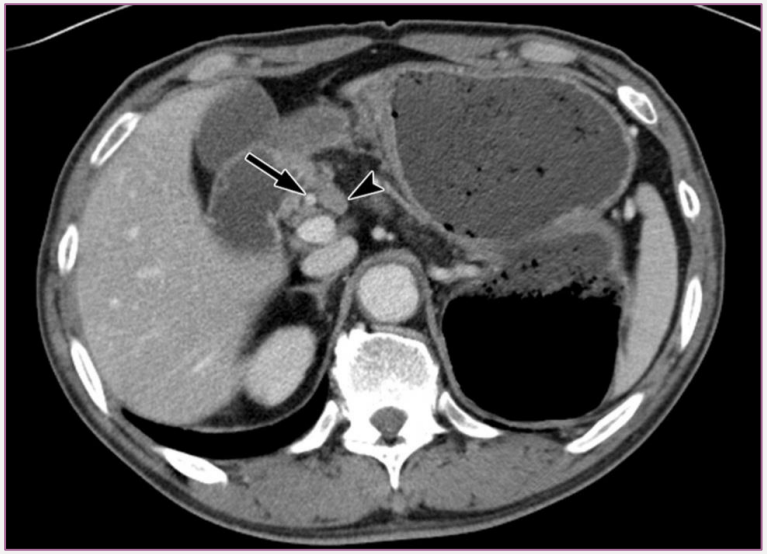

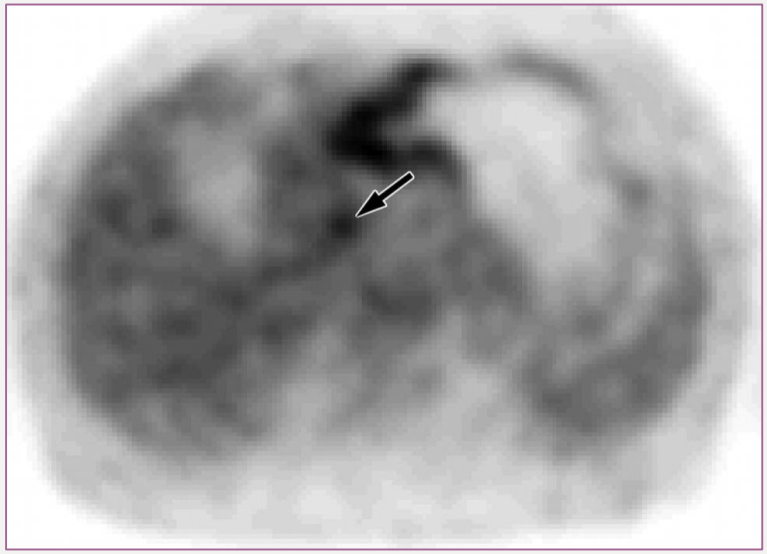

MYOCARDIAL PET/CT IMAGING

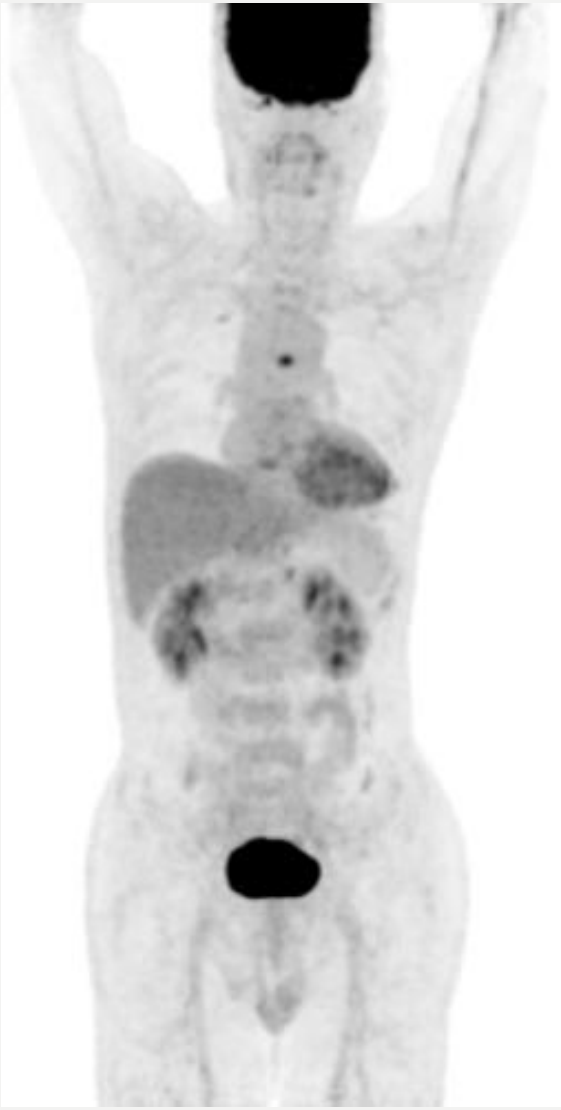

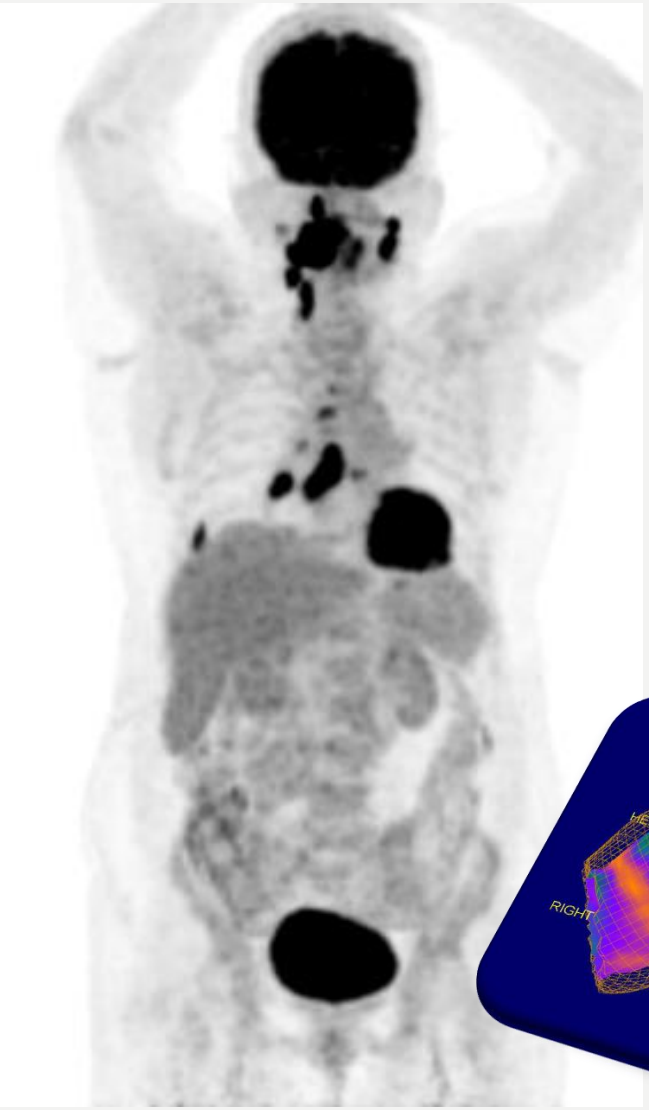

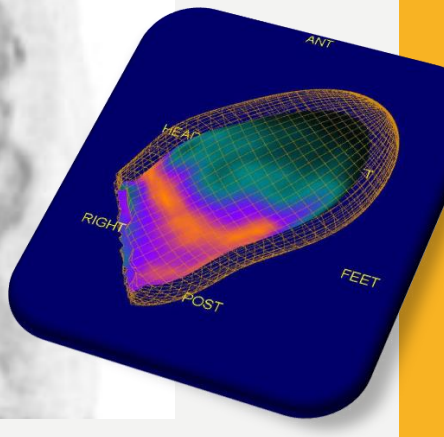

WHOLE BODY ACQUISITION

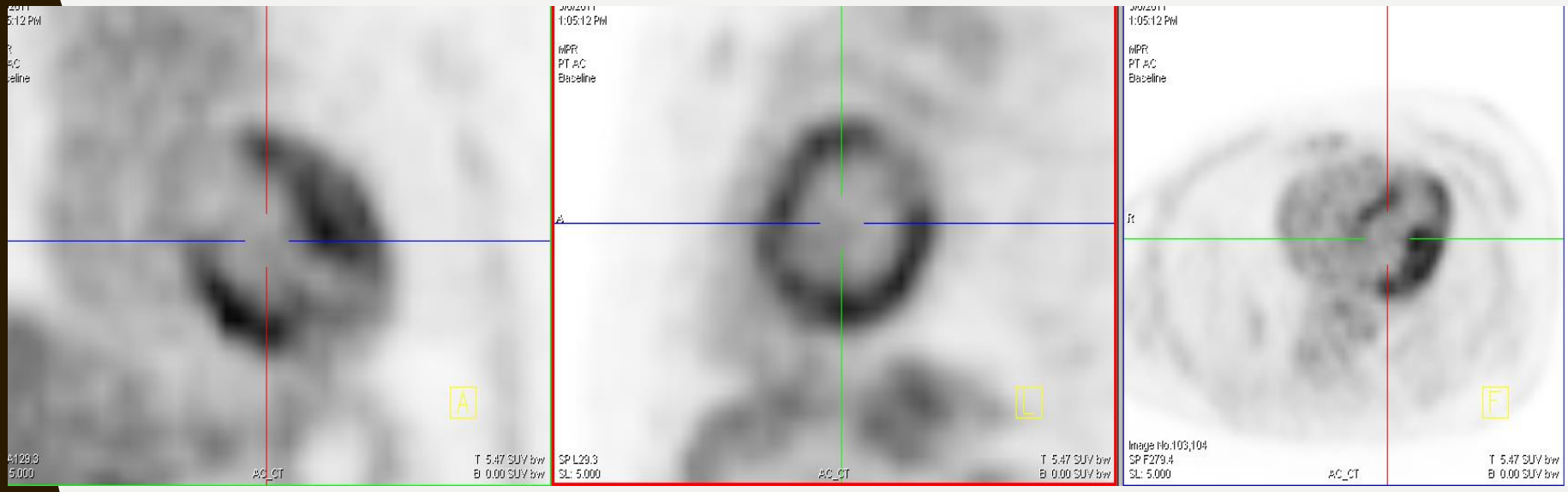

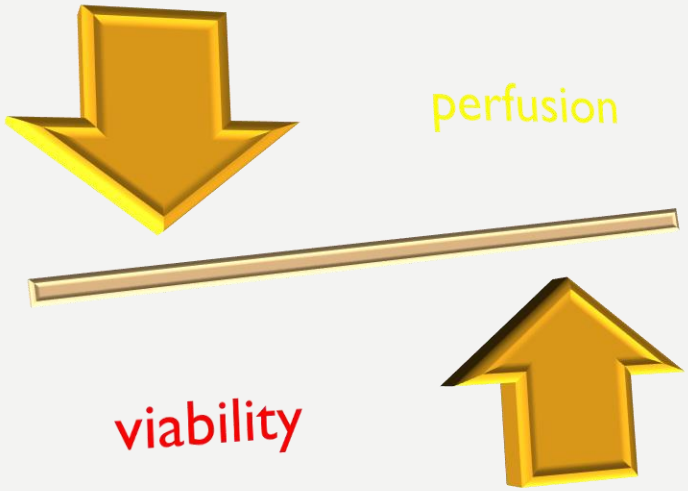

PATTERN 1

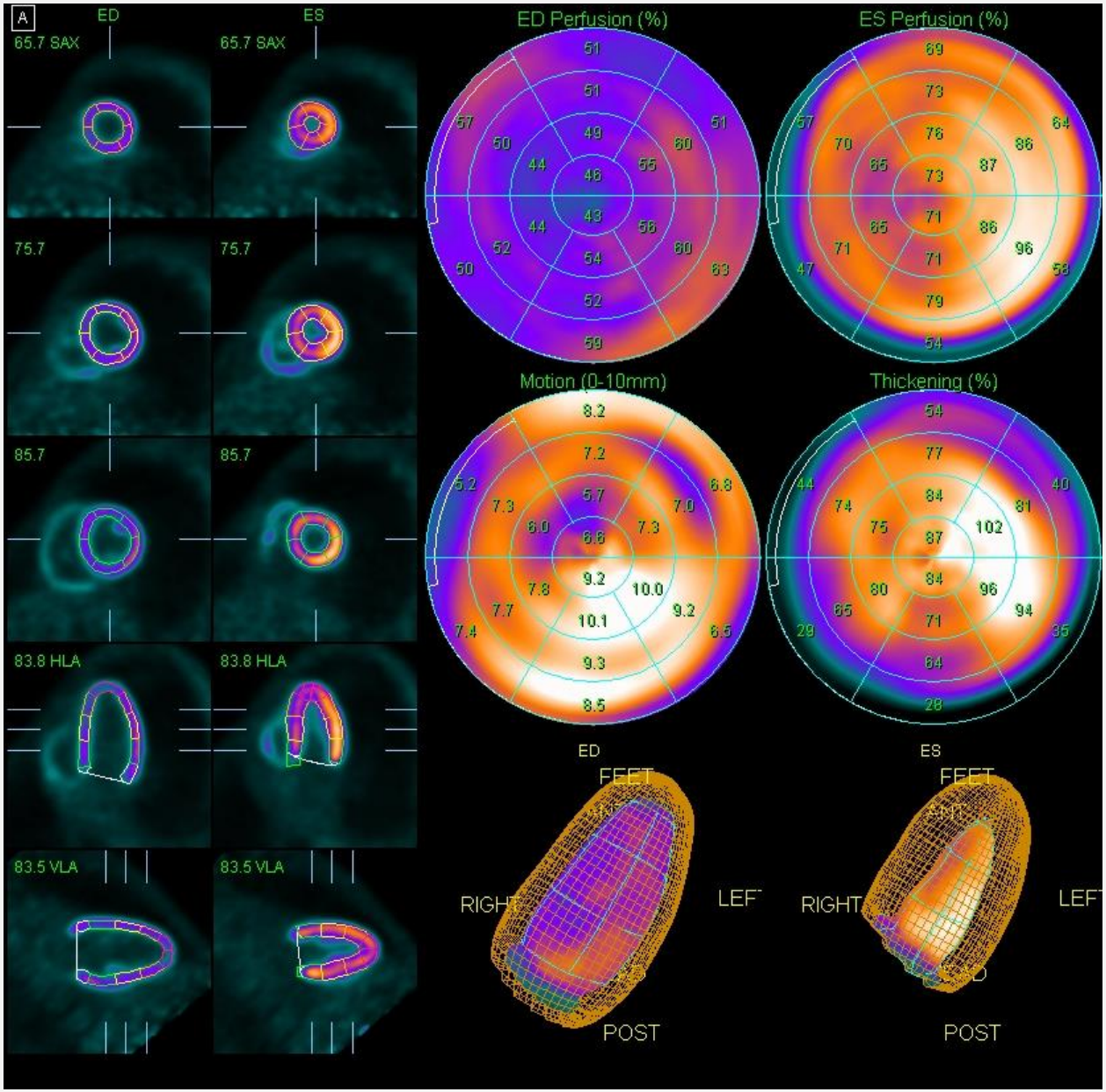
A
ED
ES
65.7 SAX
65.7 SAX
75.7
75.7
85.7
85.7
83.8 HLA
83.8 HLA
83.5 VLA
83.5 VLA
ED Perfusion (%)
ES Perfusion (%)
Motion (0-10mm)
Thickening (%)
ED
ES
FEET
FEET
RIGHT
RIGHT
POST
POST

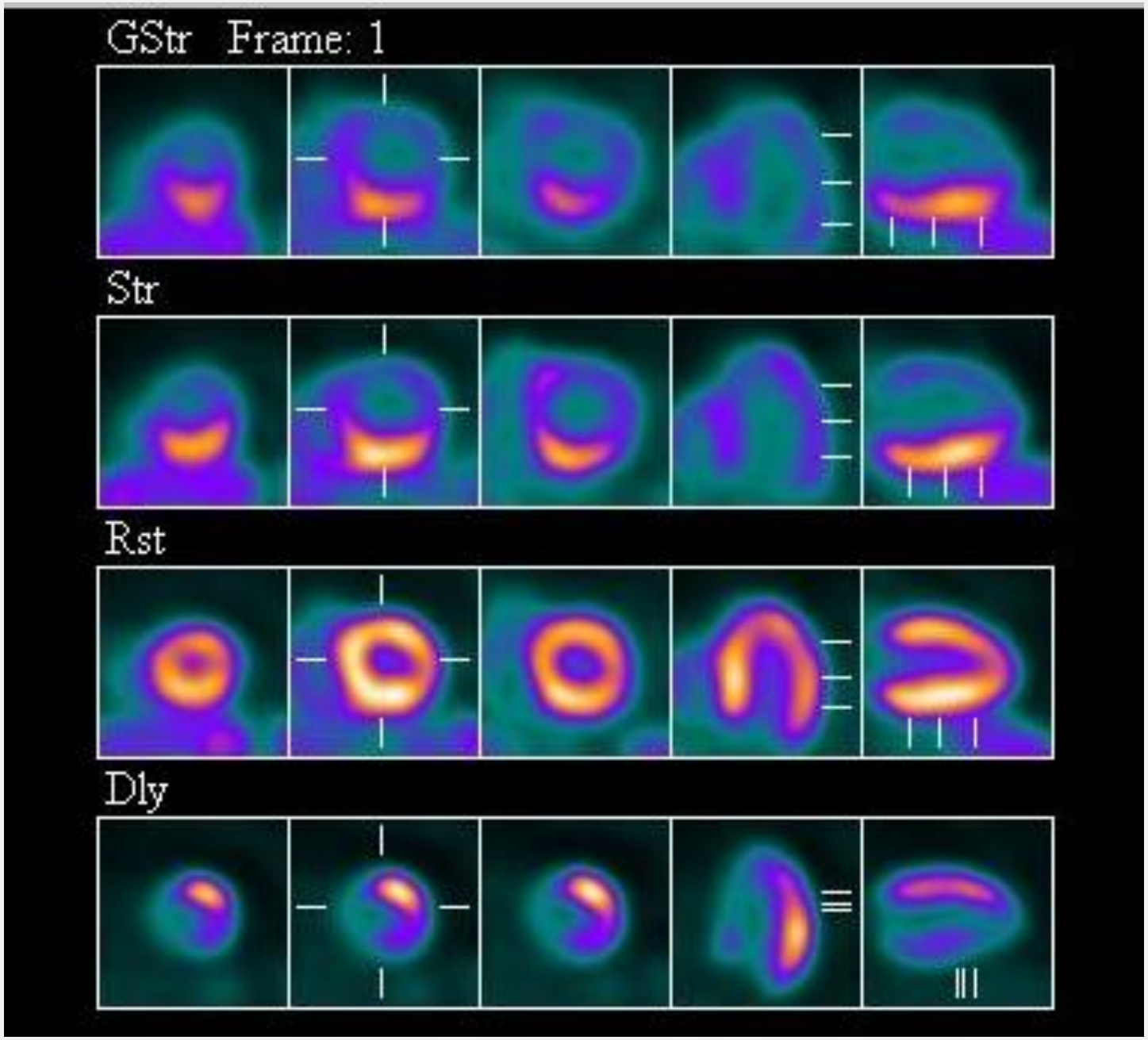
GStr Frame: 1
Str
Rst
Dly

Functional MRI

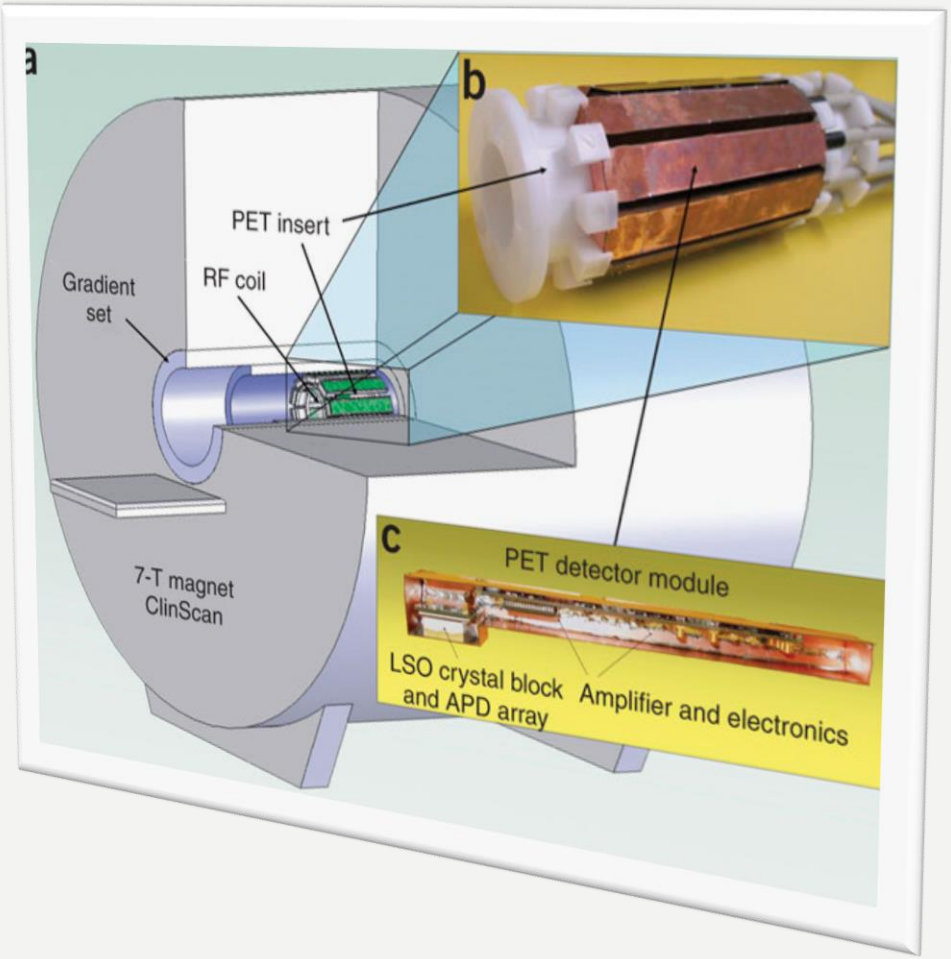

FUNCTIONAL MRI 3.0 TESLA

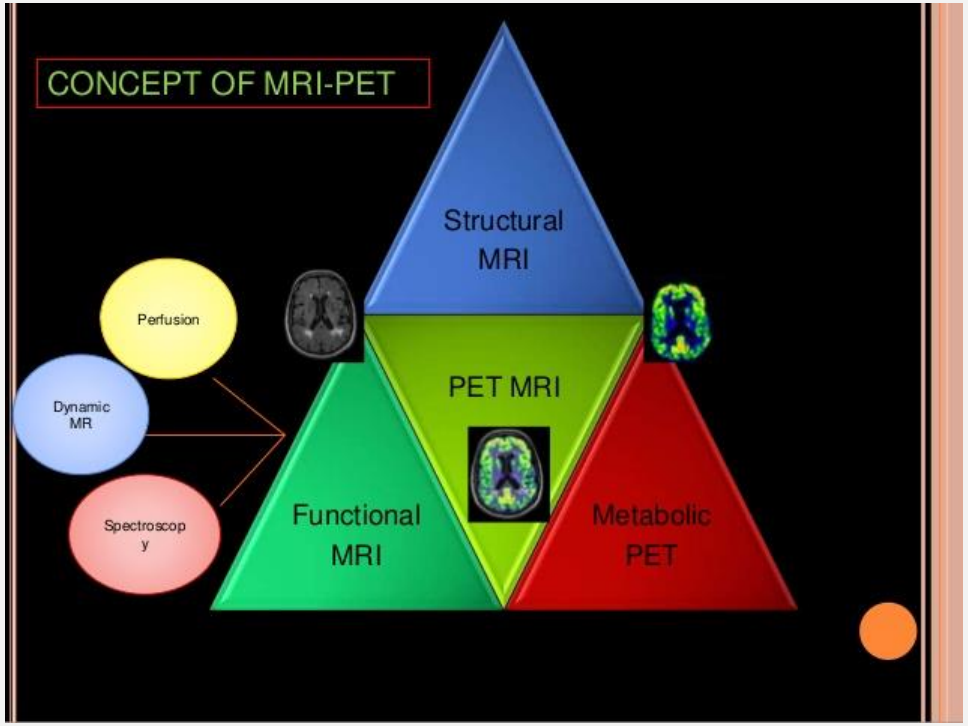
CONCEPT OF MRI-PET
Structural MRI
Perfusion
Dynamic MR
Spectroscopy
PET MRI
Functional MRI
Metabolic PET

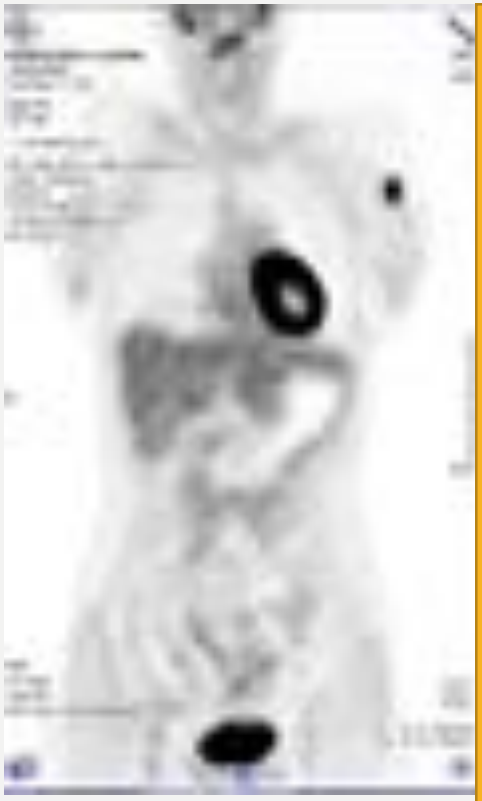

Fdg pet

Dwi mri

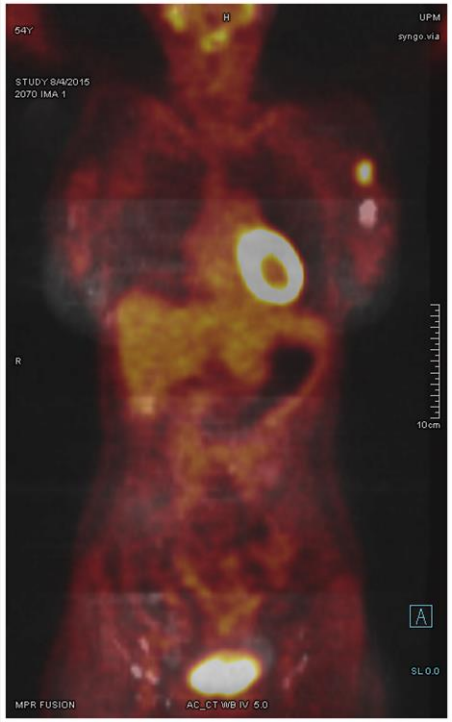

MRI-PET

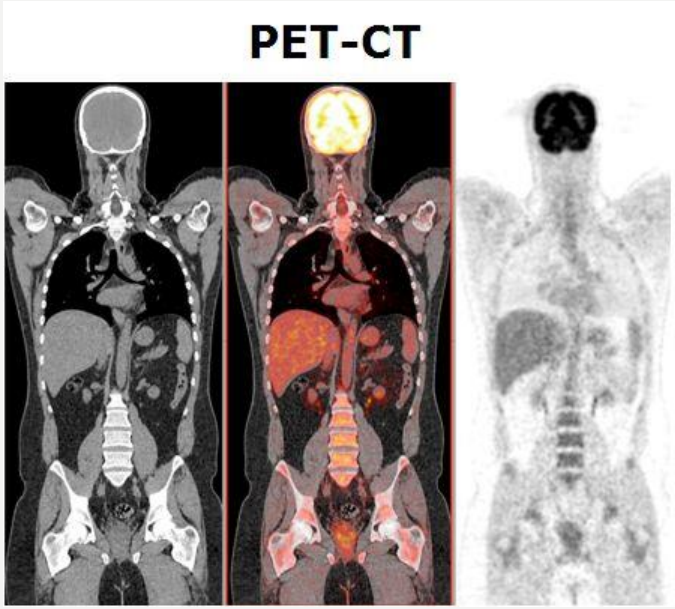
PET-CT

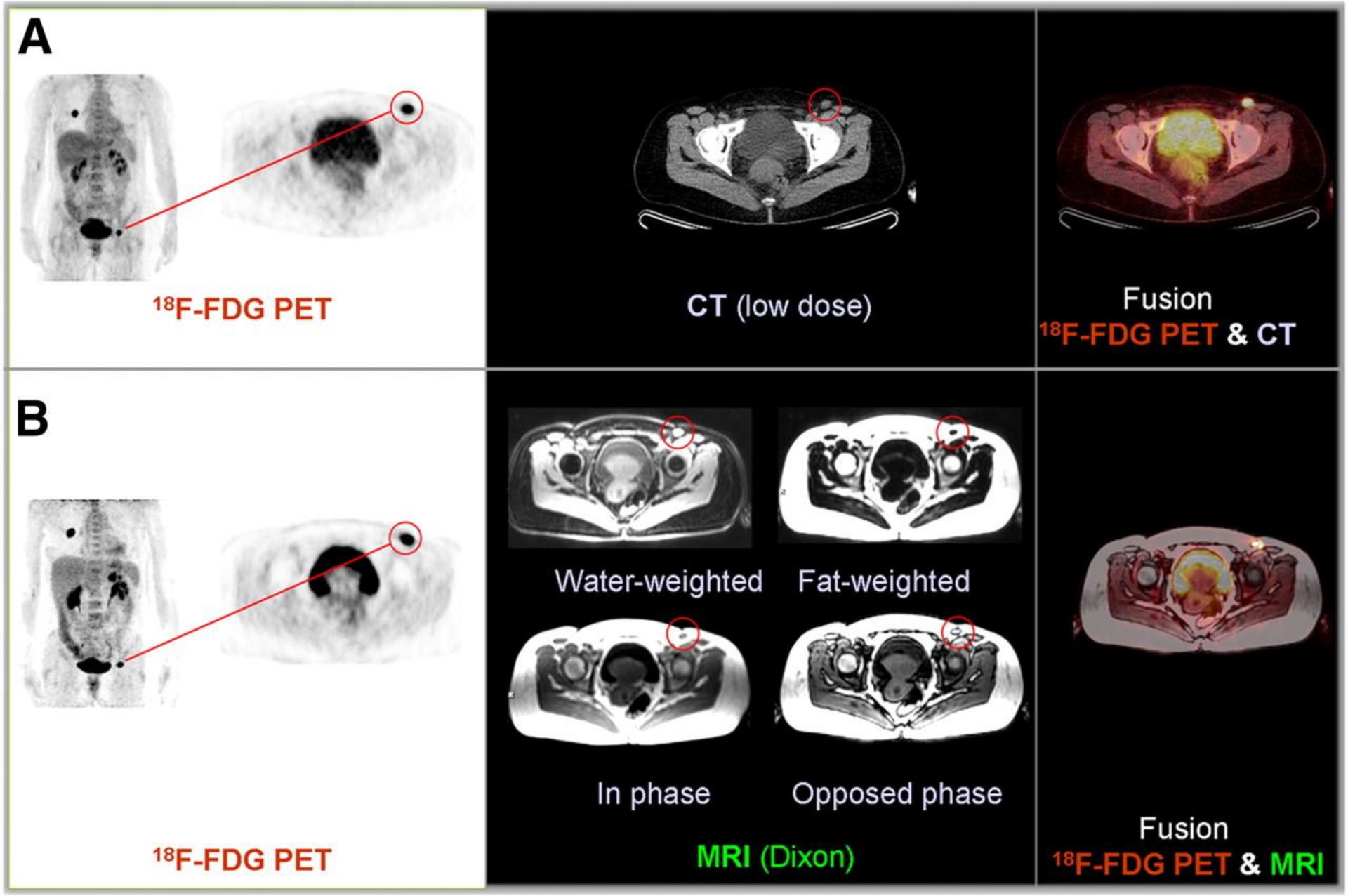
A
18F-FDG PET
CT (low dose)
Fusion
18F-FDG PET & CT
B
18F-FDG PET
Water-weighted
Fat-weighted
In phase
Opposed phase
MRI (Dixon)
Fusion
18F-FDG PET & MRI

MRI-Ultrasound Fusion

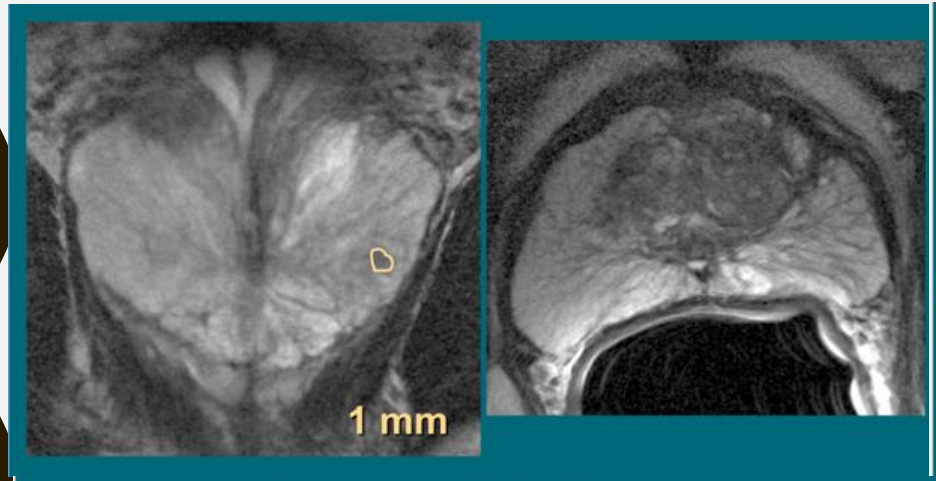
1 mm

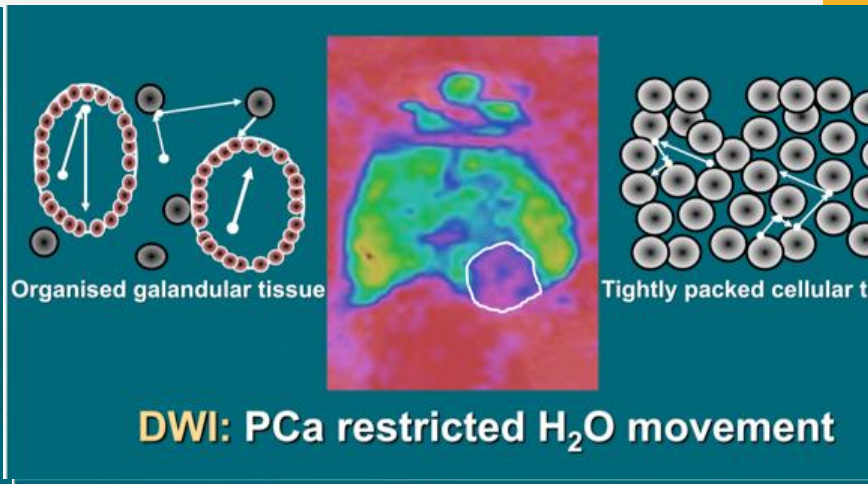
Organised galandular tissue
Tightly packed cellular t
DWI: PCa restricted H_2O movement

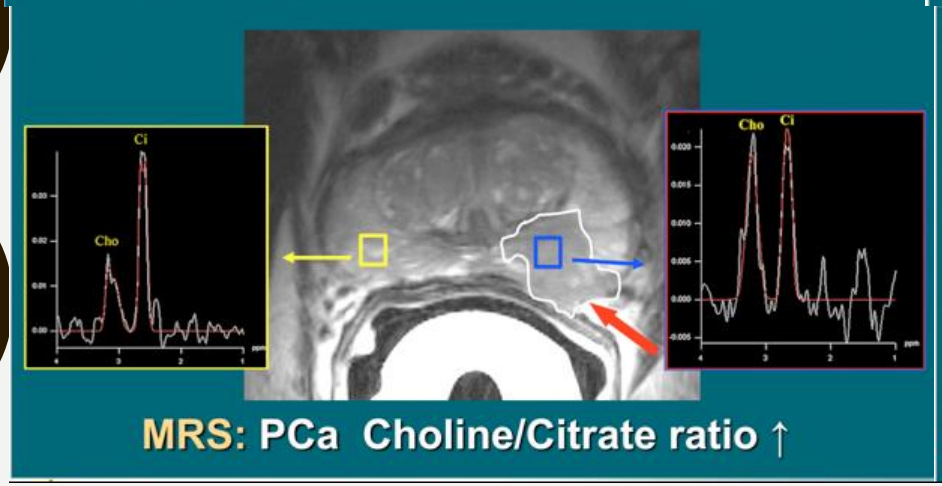
Ci
Cho
Cho
Ci
MRS: PCa Choline/Citrate ratio ↑

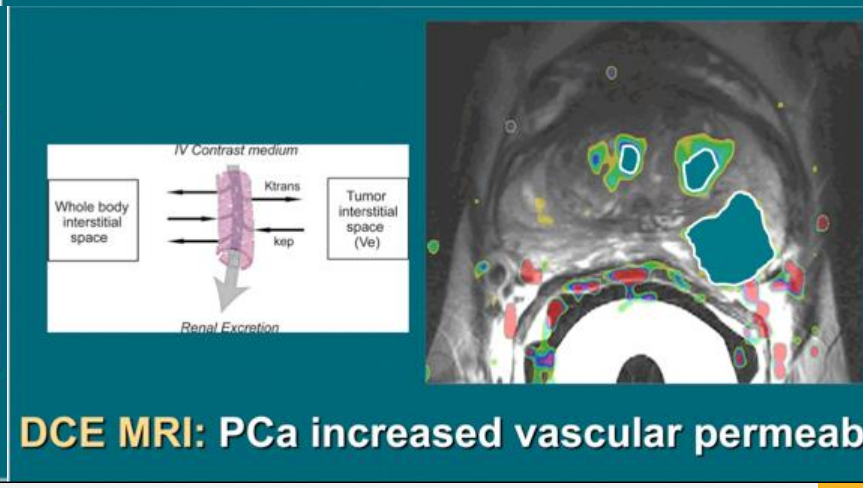
IV Contrast medium
Whole body interstitial space
Ktrans
kep
Tumor interstitial space (Ve)
Renal Excretion
DCE MRI: PCa increased vascular permeab

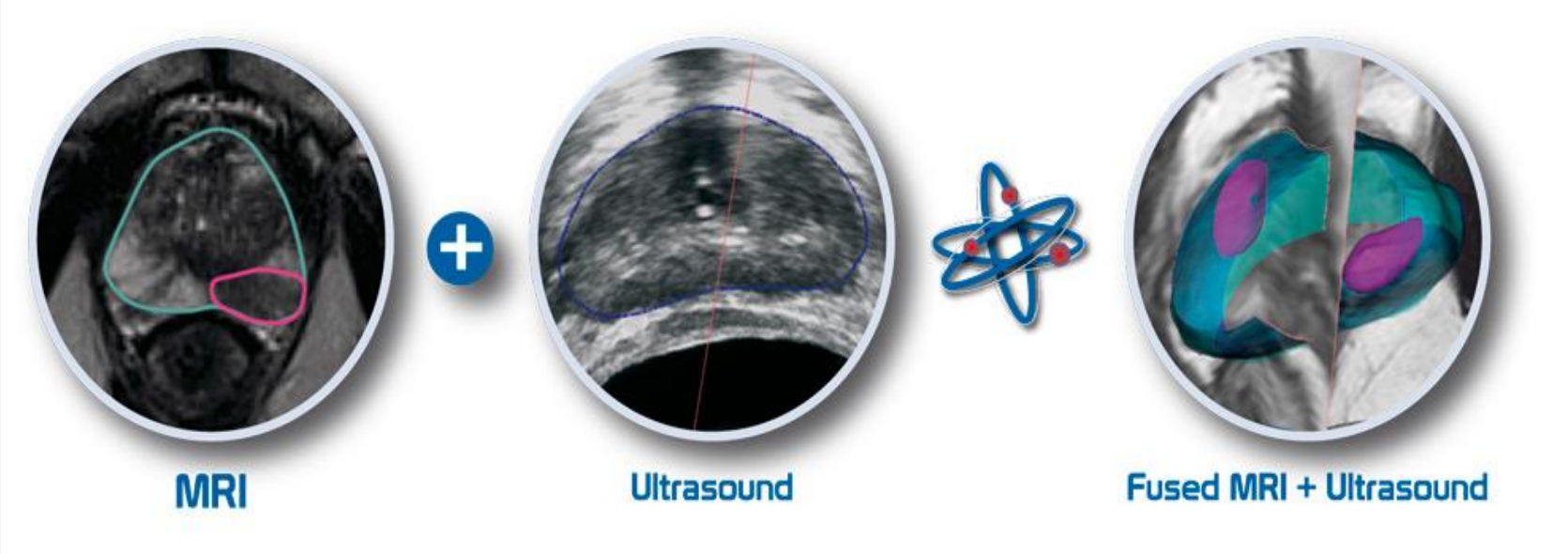
MRI
Ultrasound
Fused MRI + Ultrasound

THANK YOU